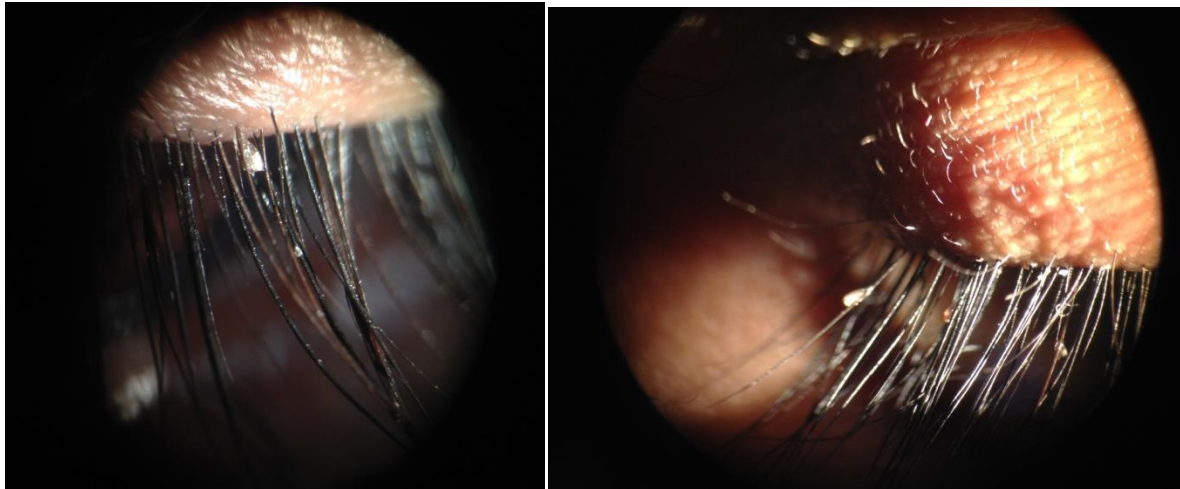
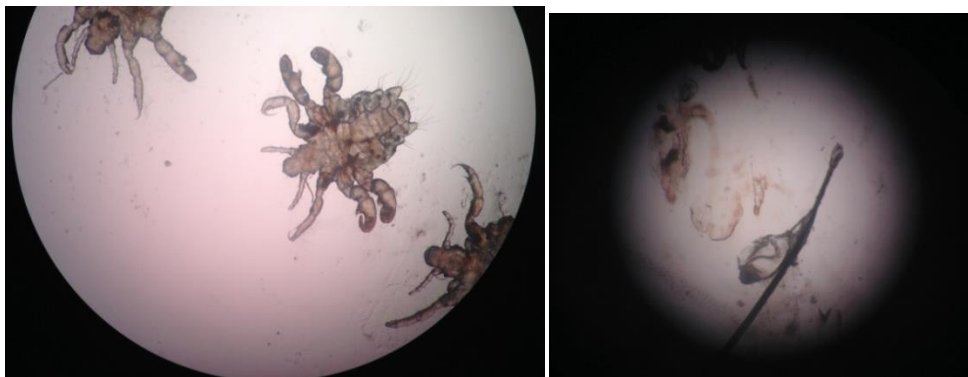


Phthriasis Palpebrarum

A female of 30years presented with itching and redness of the eyelids for 2-3 weeks. The lids were hyperemic with exfoliation of skin and white flakes adhering to the eyelashes similar to blepharitis. Slit-lamp examination revealed multiple lice on the eyelashes of both the eyes with translucent oval eggs attached to the eyelashes. Pubic and axillary hair was not affected. The adult lice and eyelashes with nits were picked up and examined under microscope confirming pubic louse (Phthriasis pubis). The patient was treated with manual removal, application of petroleum jelly and advised good hygiene. Family members were also examined and not found to be infested.



Transparent oval nits of Phthriasis pubis seen attached to eye lashes

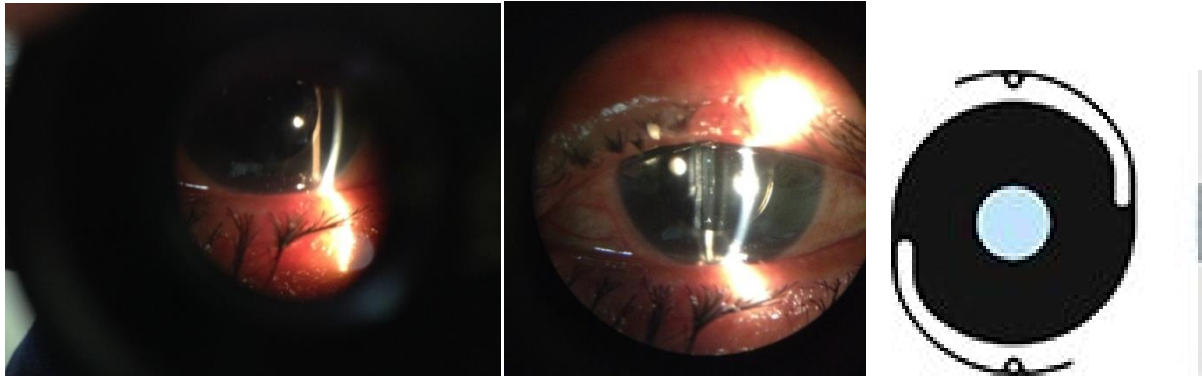


Phthriasis pubis and nit attached to the cilia

Courtesy: Dr. Taskin Khan

Aniridia Implant

A 50year old female presented with painless diminution of vision with glare in her RE following cataract surgery elsewhere 2mths back. Her vision was CF at 3mts. The patient was successfully treated of traumatic aniridia with aphakia by implanting an aniridia implant. Her post operative vision was 6/9 with no glare.



First postoperative day after aniridia implant and Aniridia IOL implant

Courtesy: Dr. Taskin Khan